

The Journal of  
**Thoracic and Cardiovascular Surgery**

**Congenital cystic adenomatoid malformation in a middle-aged woman with  
hemoptysis**

Iskander Al-Githmi, Hassan Kanaan, Nadia Batawil and Irfan Mamoun  
*J Thorac Cardiovasc Surg* 2004;127:1833-1834

The online version of this article, along with updated information and services, is  
located on the World Wide Web at:

<http://jtcs.ctsnetjournals.org/cgi/content/full/127/6/1833>

*The Journal of Thoracic and Cardiovascular Surgery* is the official publication of the American Association for Thoracic Surgery and the Western Thoracic Surgical Association. Copyright © 2004 American Association for Thoracic Surgery

## Congenital cystic adenomatoid malformation in a middle-aged woman with hemoptysis

Iskander Al-Githmi, MD, FRCSC, Hassan Kanaan, MD, Nadia Batawil, MD, and Irfan Mamoun, MD, Jeddah, Saudi Arabia



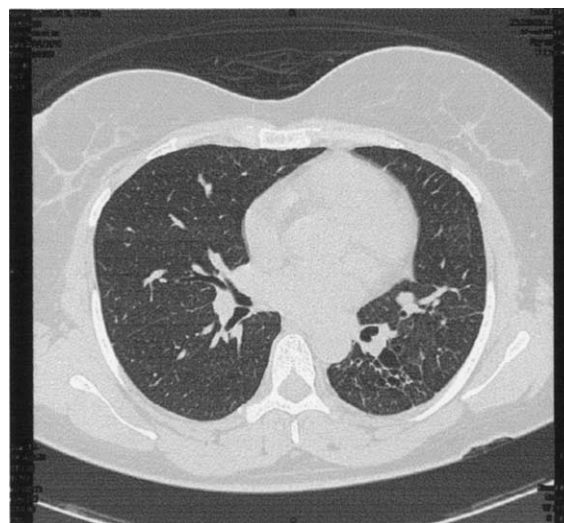
Al-Githmi

**C**ongenital cystic adenomatoid malformation (CCAM) is a rare pulmonary malformation that mostly affects newborn infants. Some of the lesions may be delayed until school age and adolescence. It usually is seen in the form of repeated respiratory tract infection. We report a case of CCAM type 1 (Stocker classification) with a presentation of hemoptysis.

### Clinical Summary

A 42-year-old woman with no previous history of respiratory problems sought treatment for recurrent hemoptysis and exertional shortness of breath. Results of the physical examination were unremarkable except for a right thyroid nodule. A high-resolution computed tomographic scan of the chest showed honeycomb bronchiectatic changes of moderate degree involving the lower lobe of the left lung (Figure 1). Results of transthoracic echocardiography, pulmonary function tests, and bronchoscopy were unremarkable. A sample obtained from the right thyroid nodule by fine-needle aspiration showed follicular adenoma.

The patient underwent left thoracotomy and a left lower lobectomy. The gross pathologic examination with serial sectioning revealed multiple small cysts near the main bronchus, with the largest measuring 1.5 cm. The rest of the lung parenchyma was unremarkable. Histologic examination revealed multiple cysts measuring as large as 1.5 cm and lined with pseudostratified ciliated epithelium with multiple interspersed mucus cells (Figure 2, B and C) associated with smooth muscle, focal cartilage (Figure 2, A), and multiple neuroendocrine nests ("tumorlets," Figure 2,



**Figure 1. Bronchiectatic changes of superior segment of left lower lobe.**

D). The postoperative course was uneventful, and the patient was discharged to her home and is doing well.

### Discussion

The term *congenital cystic adenomatoid malformation* was introduced in 1949.<sup>1</sup> Stocker and coworkers<sup>2,3</sup> described four types of CCAMs, differentiating by the size of the cysts and structures. Type 0 was defined as bronchial, type 1 as bronchial/bronchiolar, type 2 as bronchiolar, type 3 as bronchiolar/alveolar duct, and type 4 as peripheral.

CCAM of the lung is an embryonic anomaly resulting from excessive overgrowth of the terminal bronchioles. It is usually unilateral, but it can be bilateral. It mostly affects newborn infants, and only rarely is the lesion delayed beyond adolescence. The main clinical presentation is repeated respiratory tract infection. Lung abscess in adulthood has been described.<sup>4</sup> CCAM's potential for malignant transformation (to bronchoalveolar carcinoma and pulmonary embryonic rhabdomyosarcoma) has been described.<sup>5,6</sup> To our knowledge, however, the case presented here is an extremely rare clinical scenario.

From the Department of Cardiovascular Diseases, King Faisal Specialist Hospital & Research Center, Jeddah, Saudi Arabia.

Received for publication Nov 14, 2003; revisions received Jan 5, 2004; accepted for publication Jan 8, 2004.

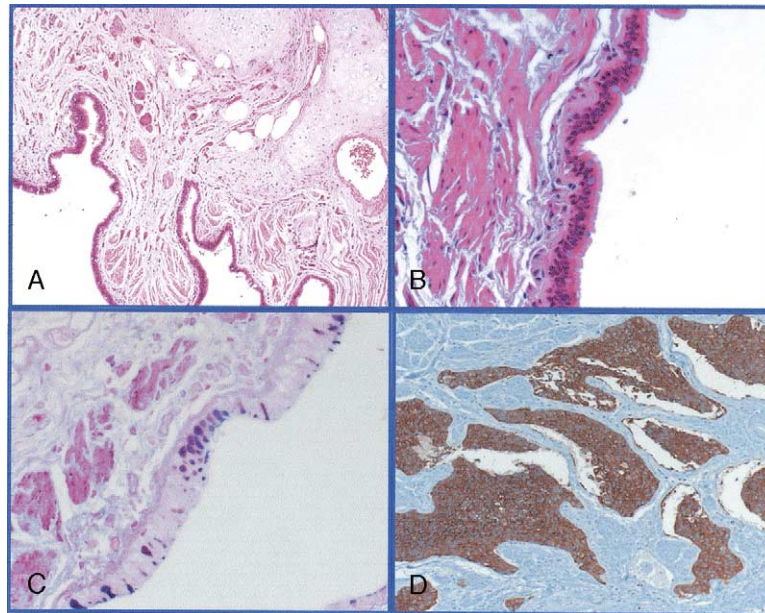
Address for reprints: Iskander Al-Githmi, MD, FRCSC, Department of Cardiovascular Diseases, King Faisal Specialist Hospital & Research Center, MBC-J16, Jeddah 21499, Saudi Arabia (E-mail: algithmi@hotmail.com).

J Thorac Cardiovasc Surg 2004;127:1833-4

0022-5223/\$30.00

Copyright © 2004 by The American Association for Thoracic Surgery

doi:10.1016/j.jtcvs.2004.01.011



**Figure 2. A, Cartilage and smooth muscle bundles (hematoxylin and eosin stain). B, Pseudostratified ciliated epithelium (hematoxylin and eosin stain). C, Mucus-secreting cells are highlighted by Alcian blue/periodic acid-Schiff stain. D, Neuroendocrine nests stain strongly positively for chromogranin A antibody.**

We believe that because of CCAM's malignant potential, repeated respiratory infection, and risk of bleeding, surgical exploration is imperative even if the patient has no symptoms.

#### References

1. Chi'in KY, Tang MY. Congenital cystic adenomatoid malformation of one lobe of a lung with general anasarca. *Arch Pathol.* 1949;47:221-9.
2. Stocker JT, Madewell JE, Drake RM. Congenital cystic adenomatoid malformation of the lung: classification and morphologic spectrum. *Hum Pathol.* 1977;2:155-71.
3. Stocker JT. Congenital airway malformation: a new name and an expanded classification of congenital cystic adenomatoid malformation of the lung. *Histopathology.* 2002;41(Suppl):424-31.
4. Dahabreh J, Zisis C, Vassiliou M, Amogianni N. Congenital cystic adenomatoid malformation in adult presenting as lung abscess. *Eur J Cardiothorac Surg.* 2000;18:720-3.
5. de Perrot M, Pache JC, Spiliopoulos A. Carcinoma arising in congenital lung cysts. *Thorac Cardiovasc Surg.* 2001;49:184-5.
6. Kaslovsky RA, Purdy S, Dangman BC, McKenna BJ, Brien T, Ilves R. Bronchioloalveolar carcinoma in a child with congenital cystic adenomatoid malformation. *Chest.* 1997;112:548-51.

## **Congenital cystic adenomatoid malformation in a middle-aged woman with hemoptysis**

Iskander Al-Githmi, Hassan Kanaan, Nadia Batawil and Irfan Mamoun  
*J Thorac Cardiovasc Surg* 2004;127:1833-1834

### **Continuing Medical Education Activities**

Subscribers to the Journal can earn continuing medical education credits via the Web at  
[http://cme.ctsnetjournals.org/cgi/hierarchy/ctsnetcme\\_node;JTCS](http://cme.ctsnetjournals.org/cgi/hierarchy/ctsnetcme_node;JTCS)

### **Subscription Information**

This article cites 5 articles, 2 of which you can access for free at:  
<http://jtcs.ctsnetjournals.org/cgi/content/full/127/6/1833#BIBL>

### **Citations**

This article has been cited by 1 HighWire-hosted articles:  
<http://jtcs.ctsnetjournals.org/cgi/content/full/127/6/1833#otherarticles>

### **Subspecialty Collections**

This article, along with others on similar topics, appears in the following collection(s):  
**Lung - other**  
[http://jtcs.ctsnetjournals.org/cgi/collection/lung\\_other](http://jtcs.ctsnetjournals.org/cgi/collection/lung_other)

### **Permissions and Licensing**

General information about reproducing this article in parts (figures, tables) or in its entirety can be found online at:

[http://www.elsevier.com/wps/find/supportfaq.cws\\_home/permissionusematerial](http://www.elsevier.com/wps/find/supportfaq.cws_home/permissionusematerial).

An on-line permission request form, which should be fulfilled within 10 working days of receipt, is available at:

[http://www.elsevier.com/wps/find/obtainpermissionform.cws\\_home/obtainpermissionform](http://www.elsevier.com/wps/find/obtainpermissionform.cws_home/obtainpermissionform)