

Cloacal Exstrophy: Experience at King Abdulaziz University Hospital, Jeddah, Saudi Arabia

JAMAL S.D. AL-RAHMAN, FRCS(I), OSAMA M. RAYES, FRCS(I), SABAH S. MESHREF, FRCS(I),
MOHAMMAD MUZAFFER, FRCS(I), and YASIR S. JAMAL, FRCS(I), FICS
*Department of General Surgery, Faculty of Medicine & Allied Sciences,
King Abdulaziz University, Jeddah, Saudi Arabia*

ABSTRACT. Cloacal exstrophy is one of the complex anomalies which challenge the pediatric surgeons infrequently. At King Abdulaziz University Hospital, Jeddah, we had the experience of managing four cases. The reconstruction was achieved in stages and involved gastrointestinal, urological, genital, and musculoskeletal systems. All the managed cases were raised as their original genotype. A fifth case died before any surgical intervention, due to a major cardiac congenital anomaly. The aim of the present study is to report such rare anomalies and to present our experience in their management.

Keywords: Cloacal exstrophy, Anomalies, Staged multidisciplinary reconstruction.

Introduction

Cloacal exstrophy (CE) is a rare form of anterior abdominal wall defect. It is different from bladder exstrophy where the bladder wall is everted and the mucosa is exstrophied with bifid penis or clitoris and wide symphysis pubis. However, in CE, in addition to the anterior abdominal wall defect, intestinal mucosa surrounded by bladder mucosa is exstrophied with associated omphalocele, genital deformity, and variable length blind-ended terminal colon with imperforated anus^[1-7].

CE is an anomaly with an incidence ranging between 1:200,000 to 1:400,000 live births in the world literature^[1,4,5,7].

Exstrophic lesions represent abnormal embryogenesis involving the cloacal membrane. Several theories have been reported to explain this phenomena but none of them

Correspondence & reprint requests to: Dr. J.S.D. Al-Rahman, P.O. Box 6615, Jeddah 21452, Saudi Arabia.
Accepted for publication: 25 February 1998. Received: 10 December 1996

could explain the prolapse of the ileum and the blind end colon with the imperforated anus. However, this was explained by Magnum^[1] who suggested a loop or loops of mid- or hind-gut prolapse between the hemibladder and became strangulated. The survival rate has been increasing in the last three decades since Rickham's^[2] first survived case in 1960. The reason for the previous high mortality was largely attributed to urosepsis and intestinal obstruction^[1,2]. However, the recent improved survival rate is attributed to the new development in parenteral feeding, neonatal and paediatric intensive care, advances in paediatric anaesthesia, plus an early multidisciplinary management and multisystem staged reconstruction^[3,4].

CE requires several operative procedures aiming at good functional results and a better quality of life. It requires gastrointestinal, urological, genital, neurosurgical, orthopaedic, and plastic operations which usually performed sequentially over a period of time. The aim of the present report is the presentation of our experience in the management of four cases of CE who were treated in the King Abdulaziz University Hospital (KAUH), Jeddah, in stage reconstruction.

Materials and Methods

Five cases with CE were referred from regional hospitals to KAUH for management. One of them died before any surgical intervention due to a major cardiac anomaly. The remaining four cases were admitted and managed over a period of seven years (1989-1995) in a multidisciplinary multisystem staged surgical reconstruction. The mean gestational age for the cases was 34.75 weeks with a mean birth weight of 2.03 kg. The mean age at referral was 39.25 days.

All cases were with the classical form of CE (Fig. 1) (everted exstrophied intestinal mucosa surrounded by two hemibladders of good size with prolapsed terminal ileum into the intestinal mucosal plate, blind end colon of variable length opened at a lower level in the intestinal mucosal plate, imperforated anus, wide symphysis pubis, ambiguous genitalia, and superiorly small granulated omphalocele). Additional anomalies were also seen (Table 1).

No cardiac anomalies were encountered in the managed cases. Three of the cases were genetically females and the fourth is a male.

After routine preliminary investigations including ultrasound, all of the cases were explored via the omphalocele. In the first step, the intestinal mucosal plate was separated from the hemibladders and exteriorized as separate stoma after reduction of the prolapsed ileum (Fig. 2). The two good hemibladders were joined and inverted, the bladder sheets were found to be of good size in the first three cases, the abdominal wall was easily closed; however, within three to four days, the wound gapped in all the three. This led to exteriorization of the bladder as exstrophy. In the fourth case, the abdominal wall defect was large. The two hemibladder urothelial sheets, after joined together, were sutured to the abdominal wall margins as a patch for closing the defect. This patient expired on the 16th postoperative day due to severe hypoxia of ARDS (Fig. 3).

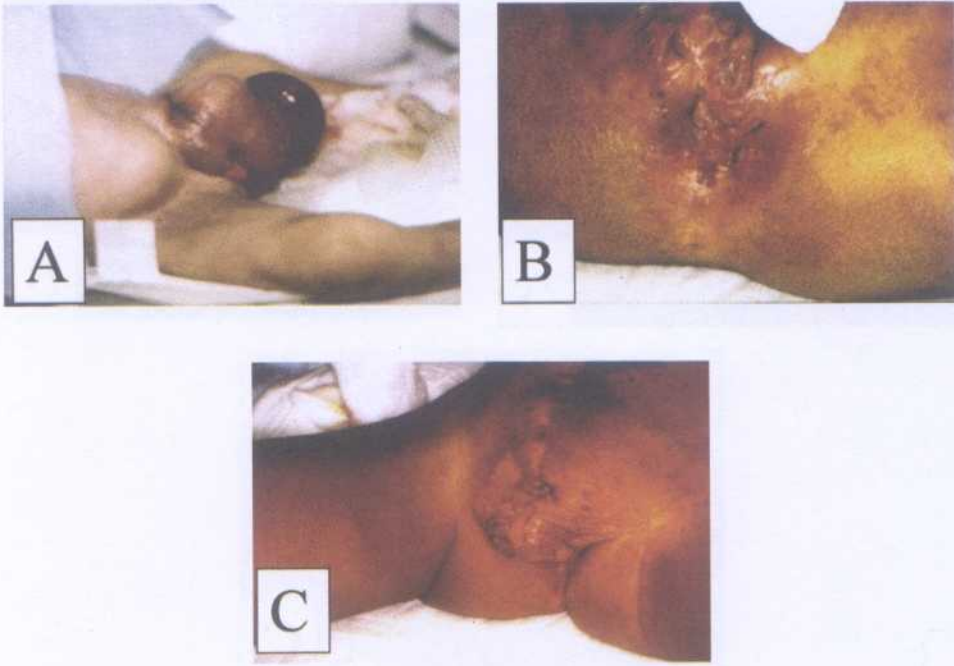


FIG. 1. Plate A: Case No. 1: Male patient at presentation pre-operatively.

Plate B: Case No. 1: Postoperative view showing the anal orifice after the posterior sagittal anorectoplasty.

Plate C: Case No. 1: Postoperative view showing the genital reconstruction with small retracted penis.

TABLE 1. Additional associated anomalies seen in the four cases of CE.

| Case | Sex | Associated Anomalies |
|------|-----|--|
| 1 | M | Left UDT, bifid penis, bifid scrotum, agenesis of right kidney + duplicate colon + double appendices |
| 2 | F | Left UDT, bifid penis, bifid scrotum, agenesis of right kidney + duplicate colon + double appendices |
| 3 | F | Vesical polyp, blind-ended vagina, left kidney agenesis |
| 4 | F | Absent lower lumbar vertebra (CRS), left lower limb anomaly, accessory rudimentary leg, and foot joins the original one on the medial aspect with 3-digits foot. |

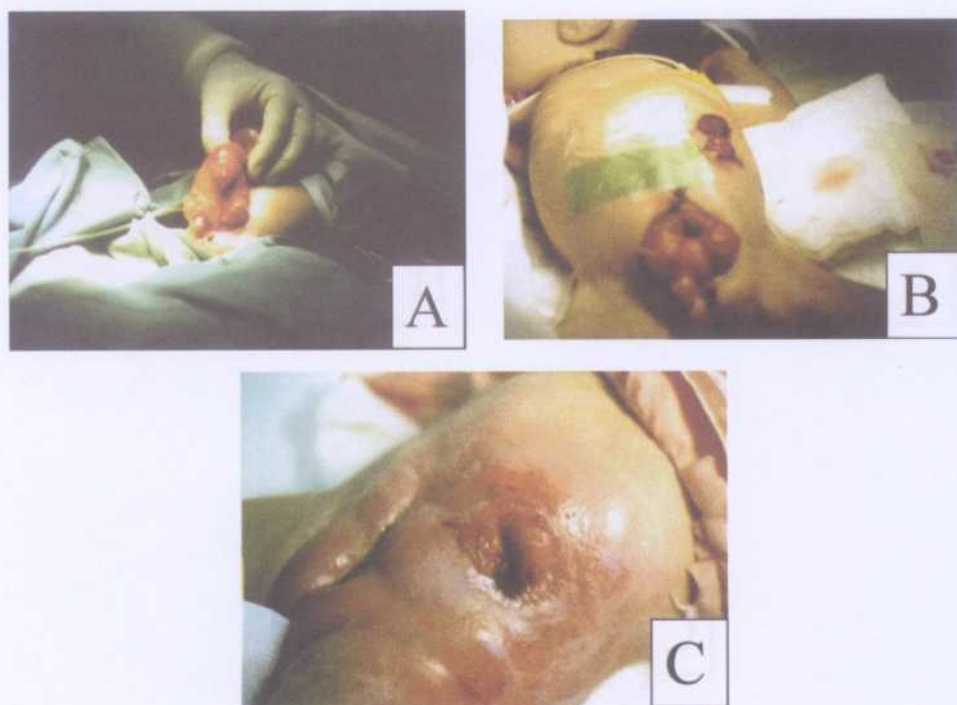


FIG. 2. Plate A: Case No. 2: Female patient at presentation pre-operatively showing the vesical polyp.

Plate B: Case No. 2: Postoperative view after separation of the bowel from the urinary bladder mucosa and exteriorized as colostomy and bladder exstrophy.

Plate C: Case No. 2: Postoperative view after closure of the bladder exstrophy and before closure of the colostomy.

The second stage was done for the three living patients one year later, which involved the bladder closure with bladder neck tightening (Fig. 2.C) (young-dees-lead better technique) with bilateral iliac osteotomy. No urinary diversion or augmentation was required as the retained bladder wall was of adequate size and bladder capacity after closure was more than 100 ml in all of the cases. The imperforated anus was treated with the posterior sagittal anorectoplasty (Pena Devries technique) around the age of two years followed by closure of colostomy six weeks later. Genital reconstruction of the three cases was done at the ages of six, four, and four years, respectively. All had several hospitalizations and additional procedures, e.g., central line insertion. The average number of admissions was ten times for each with a mean hospital stay of 17 days each time for various problems like diarrhoea, chest infection, and urinary infection.

Results

Table 2 shows the associated morbidity of the three survived cases of CE. The three cases were genitally reconstructed as their original genotype, a male and two females.

At the present stage, patients had no stomas and were wearing no appliances. There were no abdominal wall defects with cosmetically acceptable abdominal wound scars with nearly normal looking external genitalia apart from the small phallus in the male and the slightly eccentric anal orifice in two of the cases towards the right side.

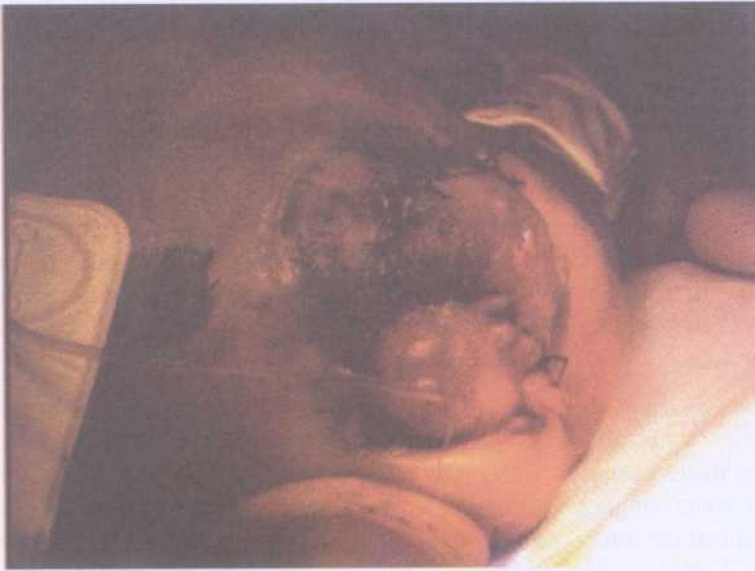

FIG. 3. Case No. 4. Male patient. The bladder wall utilized as a sheet to cover the large abdominal wall defect.

Table 2. Associated morbidity of the three survived cases of CE.

| Case | Sex | Age | Associated Morbidity |
|------|-----|---------|--|
| 1 | M | 7 years | Visible abdominal scars; small phallus; fecal soiling; stress incontinence to urine (managed by intermittent catheterization); eccentric anal orifice. |
| 2 | F | 4 years | Stress urinary incontinence managed by intermittent catheterization; stool incontinence; helped by enemias. |
| 3 | F | 4 years | Urinary incontinence; fecal soiling. |

All of the three cases were not completely continent to stool, with frequent perianal soiling and loose bowel motions occasionally. Trial of suppositories in the morning was started with encouraging results for the last few months. He could be kept clean during the night but during the day, soiling was frequent and he had to be put on the nappy.

Urinary incontinence was not absolute as there was intermittent leakage on straining. It is encouraging, by training, to evacuate the bladder hourly by suprapubic pressure and intermittent catheterization. The first two cases could be kept clean 20-30 minutes. The tight bladder neck might be the cause of stone formation seen in the boy where three

large stones were evacuated surgically during the last operative procedures for penile elongation. Sexual function could not be assessed at such a stage.

Discussion

CE is a rare and complex malformation in the anterior abdominal wall resulting from disturbed embryogenesis of the mesoderm, urorectal septum, and the cloacal membrane. This abnormality was described in 1709 by Littre^[1] and the first survivor was reported by Rickham^[2] in 1960. It was associated with high mortality from urosepsis and intestinal obstruction in addition to difficult care and social unacceptance because of the complex appearance and continuous urofecal flow^[3-5,11]. In the last three decades since Rickham's first survival report, the mortality rate was decreased, particularly in the last decade due to the recent advancement in surgical techniques, intensive neonatal and paediatric care, and sophisticated modalities of monitoring which facilitate a safer anaesthesia. In the absence of associated lethal anomaly (e.g., congenital heart disease), the survival rate approached 86%^[1]. However, morbidity associated with inadequate fecal and urinary continence and sexual function, although improving, was still high.

In the present study, the mortality (25%) and morbidity are similar to these reported previously^[1,3,5]. In addition to malformation of the lower urogenital and the gastrointestinal tract, the upper urinary tract might also be associated with some anomalies like duplex ureter, single kidney, or abnormal kidney position. More often it is associated with a spinal deformity, e.g., myelomeningocele and spinal cord tethering, and limb deformity. Lethal cardiac anomalies might also occur and its absence is usually associated with a high survival rate^[5,12]. In the present cases, some of these anomalies were seen (see Table 1) and cardiac anomaly was incriminated in the loss of the fifth case which died before any surgical intervention. The condition can be diagnosed by clinical examination but the screening of the associated anomalies require diagnostic measures (e.g., ultrasonography, CT scan) and other diagnostic modalities^[6,8,11,13].

The aim of treatment is to have functional reconstruction of the musculoskeletal, urological, gastrointestinal, and genital systems to facilitate nursing care and social support.

The key of success in management of these cases is the early multidisciplinary management and multisystem staged reconstruction. It is worth mentioning that we adopted this policy in our patients and utilized the available advanced technology of the intensive neonatal and paediatric care and paediatric anaesthesia in our hospital. From the surgical point-of-view, we started our early staged management with the separation of the intestinal plate from the urinary tract to avoid urosepsis (Fig. 3.B) In this phase, tubularization of the exstrophied caecal plate, when possible, is always recommended to preserve as much of the gut length as possible with ileocecal valve retainment. This helps to decrease the fecal flow and electrolyte disturbances. The blind end tail gut can then be exteriorized as end stoma or its proximal end fashioned as mucous fistula after separating it from the caecal plate. Colostomy or caecostomy associated with nearly formed stool thus decreases the morbidity associated with fluid loss and electrolytes imbalance. The two hemibladders then joined together in the midline with or without in-

version at the same time. Bladder augmentation might be required when the bladder capacity is small in the second phase and with adequate capacity, bladder closure and bladder neck narrowing (Young-deers lead better technique)^[1] will improve urinary continence (Fig. 2.C). This cannot be done without approximation of the widely separated pubic bones by pelvic osteotomy which we did in all of our cases. It is easy to bring the pubic bones together without osteotomy in the first 48 hours of life^[3,5]. Bladder closure with bladder neck tightening can be done between six months to one year of age during which growth and development will take place; but prolongation of this step might predispose to bladder fibrosis and bleeding urinary infection^[3-5].

The urinary continence depends on adequate bladder capacity and outlet control. In our cases, inspite of the good capacity, urinary bladder patients are not completely continent due to the weak outlet control. In the future, better control might be achieved, if necessary, with further improvement of the bladder capacity by augmentation with iléal loop or gastrocystoplasty or caecocystoplasty and the outlet control can be managed by further bladder neck reconstruction, Mitrofanoff procedure, or ileal loop nipple for intermittent catheterization^[4,9,14,15]. Longaker *et al*^[15] reported the technique which combined the augmentation with control of the outlet at the first stage as they are augmenting the bladder halves with the caecal plate with exteriorization of the tip of the appendix for intermittent catheterization but metabolic disturbances have to be considered.

In the third phase, colonic pullthrough by posterior sagittal anorectoplasty which we did in our cases or abdominoperineal approach between one to three years followed by closure of colostomy^[16,17]. Finally, reconstruction of the genitalia will take place as the last phase after settlement of the fecal and urinary problems^[3,5].

All of the three survived cases were raised as their original genotype, i.e., the male as a boy and the two females as girls, based on our religious circumstances and the improved results of the surgery of the genital reconstruction^[17] in addition to the availability of the improved technique of fertility as IVF. We could achieve the relatively acceptable results by staged reconstruction, thus avoiding single staged major procedures which might increase morbidity or mortality^[3,5,7].

From the functional point-of-view, all cases reported in the literature (relatively small in number) never attained normal functional urinary or fecal control^[3-5,16,17], but this should not discourage the management of such cases. Our experience was encouraging as no stomas and no appliances were needed in our patients; their morphological appearance was acceptable.

In conclusion, CE is a complex congenital abnormality which needs early multidisciplinary management and staged multisystem reconstruction that can result in decreased mortality and morbidity in these cases with a better quality of life.

References

- [1] Welch K, Randolph J. *Pediatric Surgery*. 4th Ed. Chapter 76: 764-765.
- [2] Rickham RO. Vesicointestinal fissure. *Arch Dis Child* 1960; 35: 97: 102.

- [3] **Stolar CA, Randolph JG, Flaniqan LP.** Cloacal exstrophy, individualized management through a staged surgical approach. *J Pediatr Surg* 1990; **25**: 505-507.
- [4] **Ricketts R, Woodard J, Zwiren GT, Andrews HG, Broecker BH.** Modern treatment of cloacal exstrophy. *J Pediatr Surg* 1991; **26**: 444-450.
- [5] **Lund DP, Hendren WH.** Cloacal exstrophy: experience with 20 cases. *J Pediatr Surg* 1993; **28**: 1360-1369.
- [6] **Langer JC, Brennan B, Lappalainen RE, Caco CC, Winthrop AL, Hollenberg RD, Paes BA.** Cloacal exstrophy: prenatal diagnosis before rupture of the cloacal membrane. *J Pediatr Surg* 1992; **27(10)**: 1352-1355.
- [7] **Hendren WH.** Cloacal malformations: experience with 105 cases. *J Pediatr Surg* 1992; **27(7)**: 890-901.
- [8] **Babut JM, Boster D, Lotan G, Mhidia A, Fremont B.** Cloacal exstrophy: what therapeutic approach for what result? *Pediatric Bucur* 1993; **48(3)**: 259-263.
- [9] **Hendren WH.** Ileal nipple for continence in cloacal exstrophy. *J Urol* 1992; **148**: 372-379.
- [10] **Batinica S, Gagro A, Bradic I, Benjak V.** Cloacal exstrophy: a case report. *Eur J Pediatr Surg* 1991; **1(6)**: 376-377.
- [11] **Agugua NE.** Cloacal exstrophy. *West Afr J Med* 1991; **10(2)**: 190-193.
- [12] **Greene WB, Dias LS, Lindseth RE, Torch MA.** Musculoskeletal problems in association with cloacal exstrophy. *J Bone Joint Surg Am* 1991; **73(4)**: 551-560.
- [13] **Jaramillo D, Lebowitz RL, Hendren WH.** The cloacal malformation: radiologic findings and imaging recommendations. *Radiology* 1990; **177(2)**: 441-448.
- [14] **Mitchell ME, Brito CG, Rink RC.** Cloacal exstrophy reconstruction for urinary continence. *J Urol* 1990; **144**: 554-558.
- [15] **Longaker MT, Harrison MR, Langer JC, Cromblehome TM.** Appendicovesicostomy: a new technique for bladder diversion during reconstruction of cloacal exstrophy. *J Pediatr Surg* 1989; **24**: 639-640.
- [16] **Pena A, Devries PA.** Posterior sagittal anorectoplasty: important technical considerations and new applications. *J Pediatr Surg* 1982; **17(6)**: 796-811.
- [17] **Jamal YS, Meshref S, Al-Rahman D, Jamal H, Al-Ghamdi A.** Surgical and ethical aspects of intersex. In: **Lutfi A, ed.** *The proceeding book of the 4th congress of Arab association of pediatric Surgery.* Dubai 1993; 98-111.

التشوهات الخلقية المركبة في منطقة أسفل البطن : خبرة عملية في مستشفى جامعة الملك عبدالعزيز ، جدة

جمال الرحمان ، أسامة ريس ، صباح مشرف ، محمد موزفر و ياسر جمال
قسم الجراحة العامة ، كلية الطب والعلوم الطبية ، جامعة الملك عبدالعزيز ،
جدة ، المملكة العربية السعودية

المستخلص . تعتبر التشوهات الخلقية المركبة في منطقة أسفل البطن والتي تنتج عن عدم إكتمال تكوين الجدار الأمامي للبطن والمثانة البولية وجزء من الأمعاء الغلظة والتي تكون مصاحبة لانسداد فتحة الشرج وعدم تكون المستقيم ، تعتبر من أحد العيوب الخلقية النادرة والتي تحير الجراحين في طريقة علاجها . في مستشفى جامعة الملك عبد العزيز بجدة تم علاج أربع حالات من هذا النوع وهناك حالة خامسة توفيت قبل التدخل الجراحي نتيجة عيوب مضاعفة في القلب . ولقد تم تعديل الأعضاء المصابة (الجهاز الهضمي - التناسلي - العضلي) على عدة مراحل وفي جميع هذه الحالات لم يتم تغيير الجنس لدى الطفل المصاب . الهدف من هذا البحث هو القاء الضوء على هذا النوع النادر من العيوب الخلقية والاشارة إلى أهمية العلاج المرحلي ونشر نتائج علاجها .

