

Allergic aspergillus sinusitis with proptosis

K. J. DAGHISTANI, F.R.C.S.(Ed.),* T. S. JAMAL, F.R.C.S.I.,* S. ZAHER, M.D.,* O. I. NASSIF, F.R.C.S.,(C)**

Abstract

Allergic aspergillus sinusitis has recently been increasingly recognized. Five cases are discussed. All presented with proptosis, signs and symptoms of allergic rhinitis and radiological evidence of expansile masses with calcification and bony erosions involving multiple sinuses. Greenish cheesy material was seen at surgery. Histologically the lesions contained eosinophils, Charcot-Lyden crystals and fungal septate hyphae. *Aspergillus fumigatus* was grown from all cases. Surgical removal with drainage and aeration were performed. The follow-up period ranged between three to 18 months. Recurrence occurred in one patient.

Allergic aspergillus sinusitis can mimic malignant disease and should be considered in the differential diagnosis of lesions involving multiple sinuses. It should also be considered in all cases of proptosis.

Introduction

Aspergillus infection of the nose and sinuses, once thought to be a rare disease, is now being more frequently recognized. McGuirt and Harrill (1979) found a total of 115 cases of aspergillosis of the sinuses in the world literature. Stammberger *et al.* (1984) reported an increase in the number of aspergillosis of the maxillary sinuses. Aspergillosis of the paranasal sinuses used to be associated with immunosuppressed patients, diabetics or those receiving radiotherapy or cytotoxic therapy. A number of studies, however, showed the occurrence of aspergillosis of the sinuses in otherwise healthy individuals (Axelsson *et al.*, 1978; Grigoriu *et al.*, 1979; Stammberger, 1985).

There are two broad categories of aspergillus infection of the paranasal sinuses: namely invasive and non-invasive forms. The invasive form is again subdivided into the highly aggressive and lethal fulminant aspergillosis and the slowly destructive invasive aspergillosis. The non-invasive category is also subdivided into two forms: the first is called an aspergilloma and it usually affects one sinus, the second is called allergic aspergillus sinusitis (AAS) and usually involves more than one sinus.

We present five cases with proptosis. The clinical, radiological and histological features are discussed. Its similarity to malignant disease is noted.

Case reports

Case 1

A 10-year-old boy presented with left proptosis and epiphora accompanied by nasal obstruction and rhinorrhoea. There was no past history of asthma. Examination showed a single nasal polyp in the left nostril with a severely deviated septum. A diffuse firm swelling at the left medial orbital margin was seen with gross displace-

ment of the left eyeball. A CT scan demonstrated a hyperdense expansile mass with calcification occupying the left nasal cavity, ethmoid, maxillary, sphenoid and frontal sinuses. The normal bony boundaries were destroyed (Fig. 1). A left external fronto-ethmoidectomy and Caldwell-Luc operation were performed. The sinuses contained an extensively friable greenish material with a polypoidal mass and inspissated pus (Fig. 2). Swabs from all sites grew *Aspergillus fumigatus*. Histology revealed a mixture of eosinophils and neutrophils with septate hyphae. No anti-allergic treatment was given in this case but he had course of ketoconazole 200 mg orally once a day for 10 days. This child was free of recurrence 18 months post-operatively.

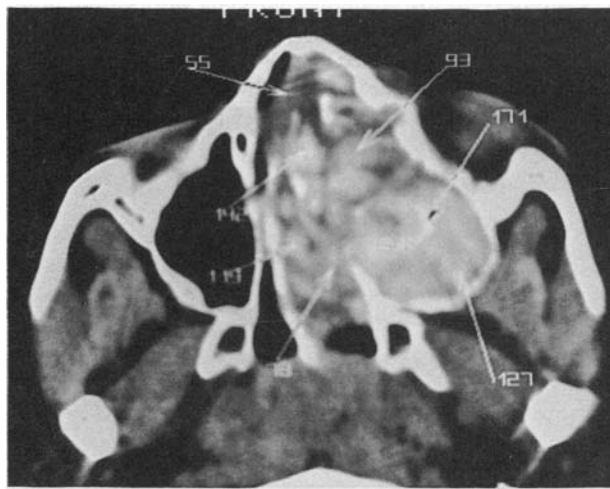


FIG. 1

CT scan showing hyperdense shadows in the paranasal sinuses of the left side.

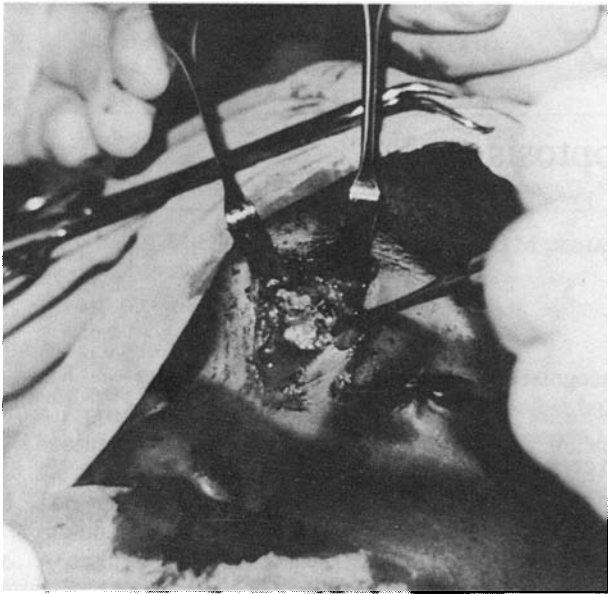


FIG. 2

External approach to sinuses with brown greenish cheesy materials.

Case 2

A 13-year-old boy was seen with right-sided proptosis for 10 years increasing in size over the last two years. No other complaints or past history of asthma was obtained. Displacement of the right eye with widening of the medial canthus was noted (Fig. 3). Examination of the nose showed the presence of an hypertrophied right middle turbinate with nasal polypi and a deviated nasal septum. A CT scan revealed an expansile mass arising from the right ethmoidal air cells with destruction of the right medial orbital wall. Extension up to the right frontal sinus was seen. A right external fronto-ethmoidectomy operation was performed revealing a cystic mass containing a cheesy material.

Culture from the ethmoidal air cells showed the presence of *Aspergillus fumigatus*. Histology confirmed the allergic and fungal nature of the disease.

Topical steroids and oral antihistamines were prescribed post-operatively. The patient was free of recurrence at three months follow-up.

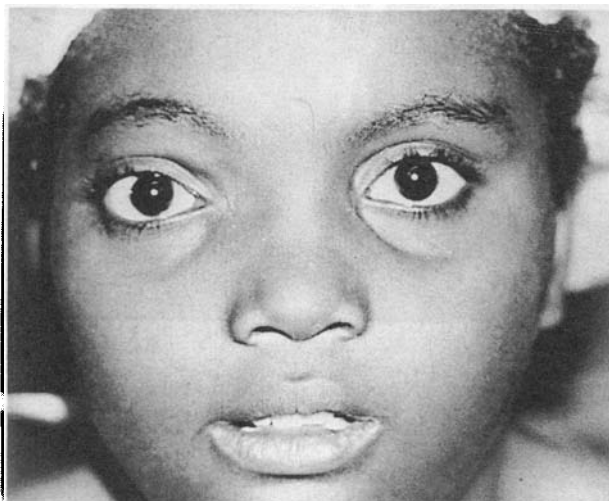


FIG. 3

Right proptosis but with no visual disturbances.

Case 3

A 29-year-old female patient presented with a history of nasal obstruction, rhinorrhoea and sneezing for four years and proptosis of the left eye for the last six months. Nasal polypi were seen in the left nasal cavity together with a polypoidal left middle turbinate. She gave a past history of nasal polypectomy but no history of asthma. A CT scan demonstrated a soft tissue mass with calcific densities filling the left ethmoid and maxillary sinuses and breaching the left medial orbital wall. A left external fronto-ethmoidectomy and Caldwell-Luc operation were performed. A mass was seen which looked friable and dark brown in colour.

Culture results indicated the presence of *Aspergillus fumigatus*. Histological examination revealed an infiltrate with a mixture of eosinophils and neutrophils. Septate hyphae were seen (Fig. 4). A course of ketoconazole 200 mg once a day was given for 10 days post-operatively. This patient developed a recurrence after one year.

Case 4

A 34-year-old man was seen with a swelling of the right medial orbital wall and slight proptosis. A large polyp was seen coming out of the right middle meatus. No past history of asthma was obtained. A CT scan showed a mass in the right ethmoidal air cells destroying the lamina papyracea and extending into the right maxillary antrum. A right external ethmoidectomy and Caldwell-Luc procedure were carried out.

Culture results indicated the presence of *Aspergillus fumigatus* and histological examination demonstrated the presence of multinucleated giant cells with many eosinophils, septate hyphae and Charcot-Lyden crystals. Post-operatively antihistamines and topical steroids were prescribed. This patient had no recurrence at three months follow-up.

Case 5

An 11-year-old girl was seen with bilateral proptosis of two years duration along with nasal obstruction, rhinorrhoea and sneezing (Fig. 5). There was no past history of asthma. Multiple nasal polypi were seen filling both nasal cavities. A CT scan revealed a large expanding lesion involving and enlarging the ethmoid cells. The frontal and sphenoidal sinuses on both sides were involved. The walls of the sinuses were eroded (Fig. 6) and the mass showed some hyperdensity. A left external frontoethmoidectomy with sphenoidectomy and left Caldwell-Luc operation were performed. All the sinuses were packed with greenish-brown material.

Swabs for culture grew *Aspergillus fumigatus*. Histology showed respiratory mucosa with oedema, eosinophils, plasma cells and Charcot-Lyden crystals. Silver, impregnation staining revealed the septate fungal hyphae (Fig. 7).

A second operation was carried out on the right side four months later. Histologically the lesion was similar to that of the left side and *Aspergillus fumigatus* was grown. Post-operative treatment consisted of antihistamines and topical steroids. The child was free of recurrence at seven months follow up.

Discussion

Since first described by Katzenstien *et al.* in 1983, more

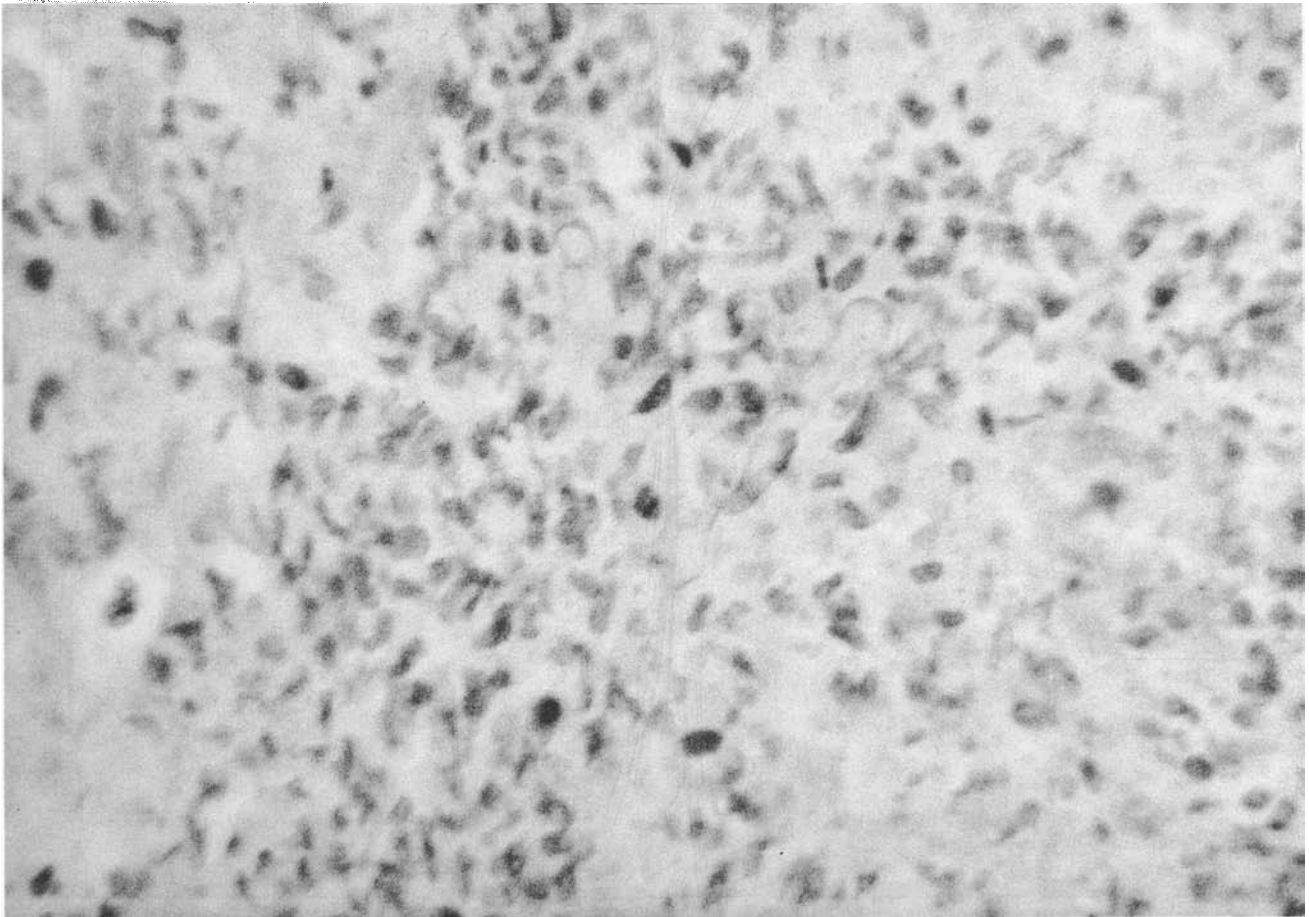


FIG. 4

Septate hyphae in the middle of the slide with ordinary staining.

cases of AAS have been reported (Meikle *et al.*, 1985; Waxman *et al.*, 1987; Jonathan *et al.*, 1989; Manning *et al.*, 1989; Philip and Keen, 1989). Allergic aspergillus sinusitis usually involves multiple sinuses in otherwise healthy patients and the majority of cases present with the clinical features of allergic rhinitis and nasal polyposis. The lesions, when advanced, will mimic malignant

disease with facial deformity and orbital displacement. All of our five cases presented with proptosis and nasal polypi but none had any visual defect or intracranial complication. Most cases will give a history of asthma although none of the cases in our series had such a history. The sinuses are typically packed with thick brown to greenish-black material with areas of concretion. The radiological appearances typically include areas of hyper-

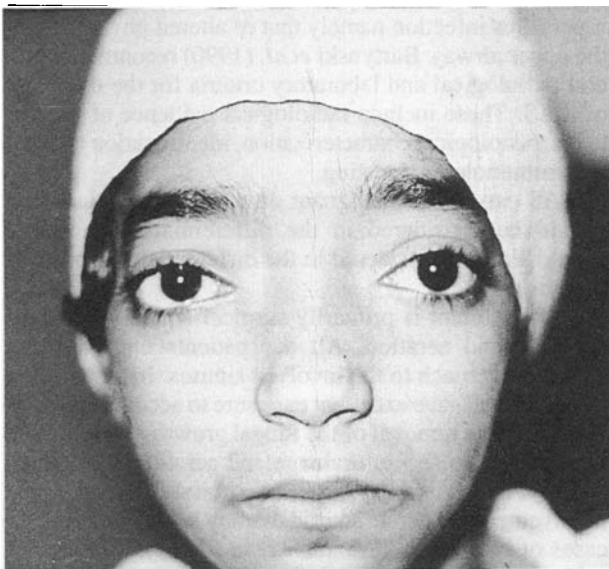


FIG. 5

Young girl with bilateral proptosis.

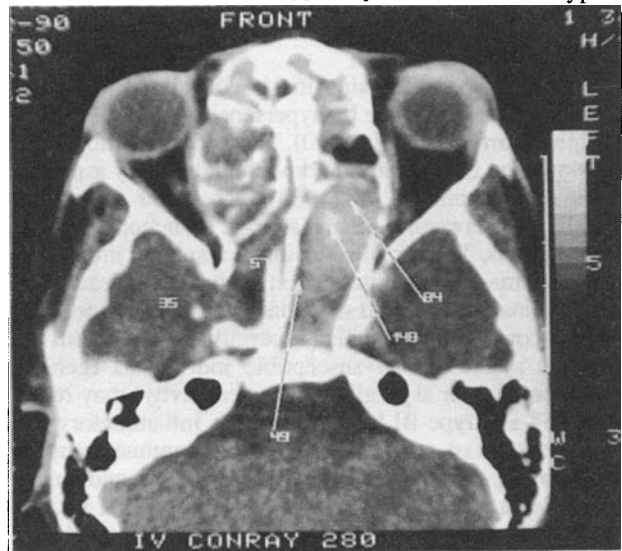


FIG. 6

CT scan showing involvement of all the sinuses and bony erosions.

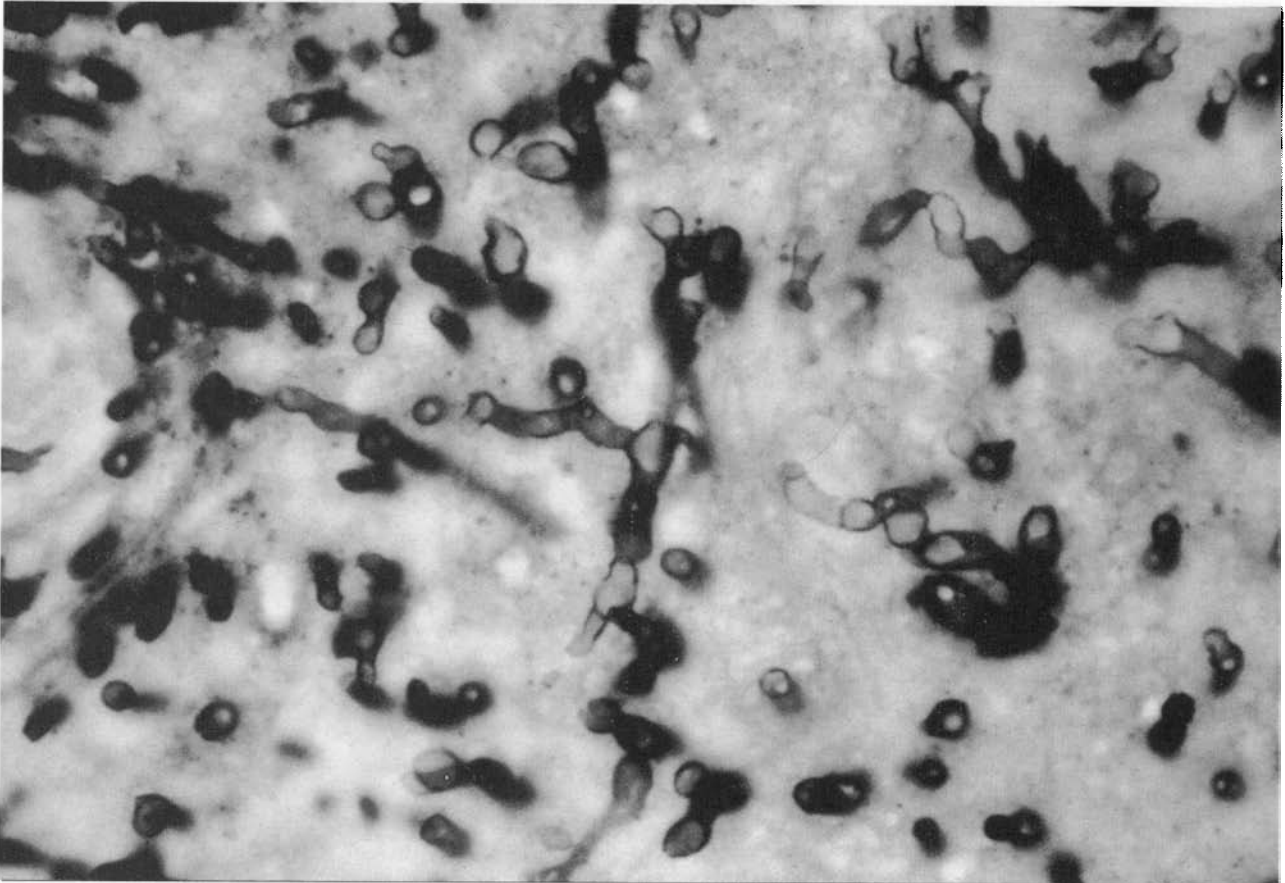


FIG. 7

Septate hyphae after silver impregnation staining.

dense calcification with bony erosions. These calcifications may resemble a metallic foreign body. Stammberger *et al.* (1984) regarded these radiological findings as pathognomonic of aspergillosis. All our five cases presented showed such X-ray appearances. The histological findings in such cases include aspergillus hyphae in eosinophilic or basophilic mucin, eosinophils and Charcot-Lyden crystals (Milroy *et al.*, 1989). The organism usually isolated is *Aspergillus fumigatus* (Katzenstein *et al.*, 1983). Bartynski *et al.* (1990) reported two cases of *Curvularia lunata*. In our series culture swabs confirmed the presence of *Aspergillus fumigatus*.

Allergic aspergillus sinusitis is considered to be the result of type I and type III hypersensitivity to the fungal antigen (Bartynski *et al.*, 1990). This process is thought to be similar to that of allergic bronchopulmonary aspergillosis. Katzenstein *et al.* (1983) recognized the strong similarities between AAS and allergic bronchopulmonary aspergillosis. The initial sinus insult results in inflammatory oedema with obstruction to the sinus ostia leading to poor drainage, stasis and secondary fungal infection. Prolonged contact of the inhaled aspergillus antigen with the mucous membrane of susceptible individuals (genetic predisposition or aspergillus hypersensitivity) may result in type I and type III hypersensitivity. Inflammatory by-products of mast cell degranulation and immune-complex tissue injury will lead to further inflammation and mucosal oedema with sinus obstruction resulting in a vicious cycle. Waxman *et al.* (1987) provided serological evidence of immune hypersensitivity to aspergillus species as an aetiological factor. They found elevated levels of IgE in six out of ten patients.

It has been suggested that the aspergillus organism becomes trapped in the bronchial tree or in the sinuses and releases an antigenic material that stimulates IgE, IgG and IgA production (Waxman *et al.*, 1987).

The environment in Jeddah (on the western coast of Saudi Arabia) may encourage the proliferation of the aspergillus organism. The warm, moist climate and the high rate of allergic, hypertrophic, vasomotor and infective rhinosinusitis may provide the other prerequisite for aspergillus infection namely that of altered physiology of the upper airway. Bartynski *et al.* (1990) recommend several radiological and laboratory criteria for the diagnosis of AAS. These include radiological evidence of pansinusitis, histological characterization, identification of fungi and immunological testing.

AAS can mimic malignant disease of the sinuses and should be considered in the differential diagnosis. It should also be considered in the differential diagnosis of proptosis.

The treatment is primarily surgical which will secure drainage and aeration. All our patients underwent an external approach to the involved sinuses. In our opinion this approach gave excellent exposure to accomplish complete and safe removal of the fungal growths and diseased mucosa and to secure drainage and aeration. Antifungal therapy is advised in cases of orbital or intracranial involvement. Systemic steroid therapy is recommended in cases of recurrence (Waxman *et al.*, 1987). Topical steroids are advised in all cases (Jonathan *et al.*, 1989). Clinical and radiological follow-up is important (Jackson *et al.*, 1987).

Two of our patients received anti-fungal therapy and one of them had a recurrence. The other three had topical steroids post-operatively but none of them had a recurrence. There was no recurrence in all of our cases at three months follow-up. One patient seen seven months and another 12 months post-operatively had no recurrence. The other three were lost to follow-up. As such we are unable to comment on the long-term recurrence rate.

Conclusion

Allergic aspergillus sinusitis is increasingly recognized. It can occur in otherwise healthy individuals not uncommonly associated with allergic rhinitis and nasal polyposis. It is non-invasive in nature and radiologically it reveals itself by calcification and bony erosion. Multiple sinuses are usually involved. The diagnosis is confirmed by histological examination and culture. AAS should be considered in the differential diagnosis of proptosis. It should also be remembered that it can mimic malignancy. The treatment is mainly surgical and an external approach is recommended.

References

- Axelsson, H., Carlsoo, B., Weibring, J., Winblad, B. (1978) Aspergillosis of the maxillary sinus: Clinical and histopathological features of four cases and a review of the literature. *Acta Otolaryngologica*, **86**: 303–308.
- Bartynski, J., McCaffrey, T., Frigas, E. (1990) Allergic fungal sinusitis secondary to dermatiaceous fungi—*curvularia lunata* and *alternaria*. *Otolaryngology—Head and Neck Surgery*, **103**: 32–39.
- Grigoriu, D., Bambule, J., Celacretaz, J. (1979) Aspergillus sinusitis. *Postgraduate Medical Journal*, **55**: 619–621.
- Jackson, I., Schmitt, III, E., Carpenter, H. (1987) Allergic aspergillus sinusitis. *Plastic and Reconstructive Surgery*, **79**: 804–808.
- Jonathan, D., Lund, V., Milroy, C. (1989) Allergic aspergillus sinusitis— an overlooked diagnosis? *Journal of Laryngology and Otolaryngology*, **103**: 1181–1183.
- Katzenstein, A. A., Sale, S. R., Greenberger, P. A. (1983) Allergic sinusitis: a newly recognized form of sinusitis. *Journal of Allergy and Clinical Immunology*, **72**: 89–93.
- McGuirt, W., Harrill, J. (1979) Paranasal sinus aspergillosis. *Laryngoscope*, **89**: 1563–1568.
- Manning, S., Vuitch, F., Weinberg, A., Brown, O. (1989) Allergic aspergillosis: A newly recognized form of sinusitis in pediatric population. *Laryngoscope*, **99**: 681–685.
- Meikle, D., Yarrington, C., Winterbauer, R. (1985) Aspergillosis of the maxillary sinuses in otherwise healthy patients. *Laryngoscope*, **95**: 776–779.
- Milroy, C., Blanshard, J., Lucas, S., Michaels, L. (1989) Aspergillosis of the nose and paranasal sinuses. *Journal of Clinical Pathology*, **42**: 123–127.
- Philip, G., Keen, C. E. (1989) Allergic fungal sinusitis. *Histology*, **14**: 222–224.
- Stammberger, H. (1985) Endoscopic surgery for mycotic and chronic recurring sinusitis. *Annals of Otolaryngology, Rhinology and Laryngology*, **94**: Supplement 119, 1–11.
- Stammberger, H., Jakes, R., Beaufort, F. (1984) Aspergillosis of the paranasal sinuses: X-ray diagnosis, histopathology and clinical aspects. *Annals of Otolaryngology, Rhinology and Laryngology*, **93**: 251–256.
- Waxman, J. E., Spector, J. G., Sale, S. R., Katzenstein, A. A. (1987) Aspergillus sinusitis: concepts in diagnosis and treatment of a new clinical entity. *Laryngoscope*, **97**: 261–266.

Address for correspondence:

Dr K. J. Daghistani,
P. O. Box 11217,
Jeddah 21453,
Saudi Arabia.
(Fax) 02-6917747

Key words: Sinusitis; Aspergillosis, allergic; Proptosis.